3. Gorlin RJ, Cohen MM Jr, Levin LS. Beckwith-Wiedemann syndrome. In: Gorlin RJ, Cohen MM Jr, Levin LS, eds. Syndromes of the Head and Neck, 4th ed. New York, NY: Oxford University Press, 2001:399–405
4. Weksberg R, Shuman C, Smith AC. Beckwith-Wiedemann syndrome. Am J Med Genet C Semin Med Genet 2005;137: 12–23
5. da Silveira EJ, Godoy GP, Lins RD, et al. Partial facial hemihyperplasia with 9 years of evolution: case report and review of the literature. Oral Surg Oral Med Oral Pathol Oral Radiol Endod 2006;102:501–505
6. Cohen MM Jr, Neri Giovanni N, Weksberg R eds. Overgrowth Syndromes. New York, NY: Oxford University Press, 2002
7. Cohen MM Jr. Beckwith-Wiedemann syndrome: historical, clinicopathological, and etiopathogenetic perspectives. Pediatr Dev Pathol 2005;8:287–304
8. Gomes MV, Ramos ES. Beckwith-Wiedemann syndrome and isolated hemihyperplasia. Sao Paulo Med J 2003;121:133–138
9. Elliott M, Bayly R, Cole T, et al. Clinical features and natural history of Beckwith-Wiedemann syndrome: presentation of 74 new cases. Clin Genet 1994;46:168–174
10. Weksberg R, Shuman C. Beckwith-Wiedemann syndrome and hemihyperplasia. In: Cassidy SB, Allanson JE, eds. Management of Genetic Syndromes, 2nd ed. New Jersey, NJ: John Wiley & Sons, 2005:101–115
11. Beckwith JB. Vignettes from the history of overgrowth and related syndromes. Am J Med Genet 1998;79:238–248
12. Shuman C, Smith AC, Weksberg R. Beckwith-Wiedemann syndrome. GeneReviews Web site. September 8, 2005. Available at: http://www.geneclinics.org/servlet/access?db=geneclinics&site=gt&id=8888891&key=hRZd42i9UtCZl&gry=&fcn=y&fw=UbTD&filename=/profiles/bws/index.html. Accessed August 10, 2006.
13. Jones KL. Beckwith-Wiedemann syndrome. In: Jones KL, ed. Smith's Recognizable Pattern of Human Malformation, 6th ed. Philadelphia, PA: Saunders, 2005:174–177
14. Slavotinek A, Gaunt L, Donnai D. Paternally inherited duplications of 11p15.5 and Beckwith-Wiedemann syndrome. J Med Genet 1997;34:819–826
15. Cytrynbaum CS, Smith AC, Rubin T, et al. Advances in growth syndromes: clinical classification to molecular delineation in Sotos syndrome and Beckwith-Wiedemann syndrome. Curr Opin Pediatr 2005;17:740–746
16. Becktor KB, Becktor JP, Karnes PS, et al. Craniofacial and dental manifestations of Proteus syndrome: a case report. Cleft Palate Craniofac J 2002;39:233–245
17. Overdiek A, Feifel H, Schaper J, et al. Diagnostic delay of NF1 in hemifacial hypertrophy due to plexiform neurofibromas. Brain Dev 2006;28:275–280

Hydroxyapatite Cement Resistant to Fragmentation Following Full Cerebrospinal Fluid Bathing

Michael G. Muhonen, MD,* Anna Lonyai, BSc,† Franklin D. Westhout, MD‡

Orange, California, USA

Abstract: Prolonged cerebrospinal fluid bathing of cranioplasty cement frequently results in breakdown of the cement implants. A 5-year-old boy with a history of severe head trauma at 2 weeks of age presented with marked protrusion of the entire superior temporal bone and inferior parietal bone. The defect was elevated by more than 1 cm and was associated with a 4.5 × 3-cm skull defect located above and behind the right ear. There also was pulsatile tissue at the depths of the defect. A computed tomographic scan taken of the head revealed an expanding skull fracture from a dural defect with underlying brain herniation. The cranial lesion was repaired with OsteoVation hydroxyapatite cement. Within 8 weeks, the fluid encased the cranioplasty site. This resolved following implantation of a shunting device. At 2 and 12 months after the repair, the implant was still palpably solid without breakdown and did not fragment despite the prolonged bathing in cerebrospinal fluid.

Key Words: Bone cements, hydroxyapatite, craniofacial

Hydroxyapatite cement has been shown to be safe and effective in a variety of craniomaxillofacial procedures such as replacement of full- and partial-thickness cranial voids and maxillofacial skeletal augmentation.[1] Despite its common use and low morbidity rate, it can have complication rates up to 32%.[1,2] The materials fail due to loosening, fragmentation, chipping and multiple fractures,[1] and especially resorption.[3]

Some of the commonly used hydroxyapatite compounds are susceptible to breakdown when exposed to (water-based) liquids such as cerebrospinal fluid (CSF)[4] and postoperative seroma.[5,6] We have observed such breakdown postoperatively in patients where the implants were exposed to CSF postoperatively. We report on a patient who received the hydroxyapatite cement implant, OsteoVation (OsteoMed, Addison, TX), which did not fragment despite being fully exposed to cerebrospinal bathing.

Materials and Methods

History, Examination, and Neuroimaging Findings

A 5-year-old boy had previously suffered severe head trauma from ''shaken-baby syndrome'' at 2 weeks of age. The patient had incurred multiple skull fractures, but no surgical intervention was undertaken at the

From the *Neuroscience Institute, Children's Hospital of Orange County, Orange, California; †Department of Biology, College of Arts and Letters, Harvard University, Cambridge, Massachussetts; and ‡Department of Surgery, Cedars-Sinai Health System, Los Angeles, California.

Address correspondence and reprint requests to Michael G. Muhonen, MD, 1201 W La Veta Ave, #101, Orange, CA 92868; E-mail: mmuhonen@aol.com

Copyright © 2008 Mutaz B. Habal, MD. Unauthorized reproduction of this article is prohibited.

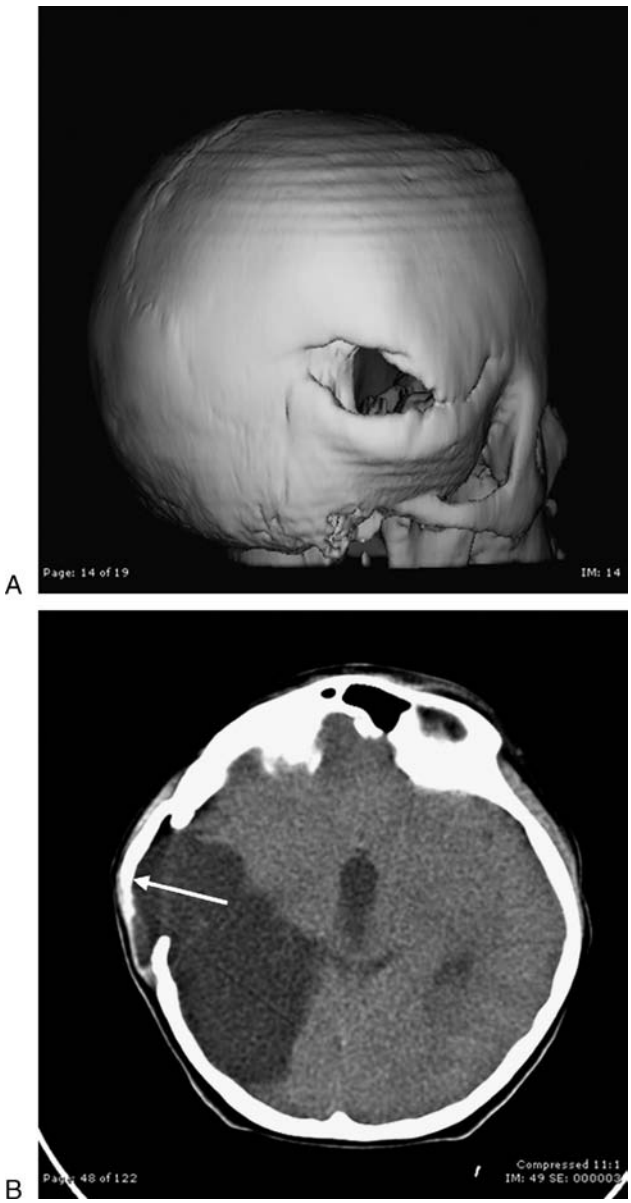

Fig 1 Preoperative CT images. (A) Three-dimensional (dimension) reconstructed CT demonstrating the right-parietal skull defect. (B) Axial CT showing protuberant bone (white arrow) below skull defect, and hemiaxial tissue through a dural defect.

time. Initial computed tomography (CT) imaging studies revealed a linear temporal/parietal bone fracture. Despite the severity of the head trauma, the child made a reasonably good recovery but experienced developmental delays and a fixed left hemiparesis. Because of social circumstances, the child was not seen in follow-up for 5 years after his skull fracture.

At 5-year follow-up, there was a marked protrusion of the entire superior temporal bone and inferior parietal bone. It was elevated relative to the profile of the contralateral side by more than 1 cm. It was associated with a 4.5 × 3-cm skull defect located above and behind the right ear (Fig 1A). In

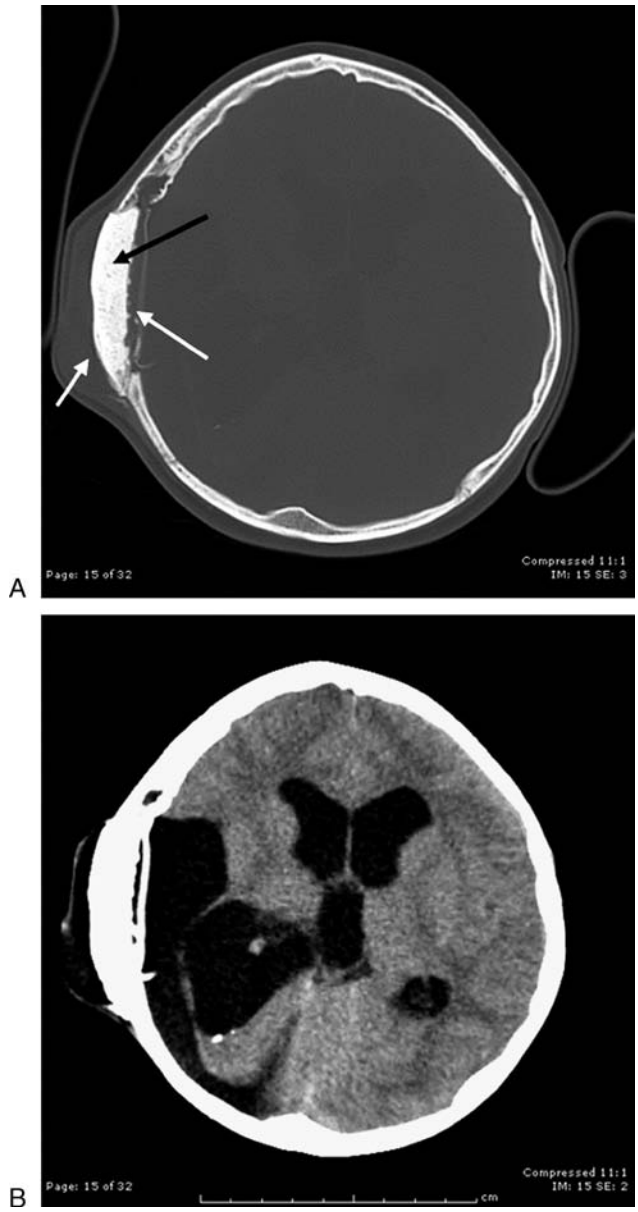

Fig 2 Postoperative CT images. (A) Postoperative axial CT (bone window) showing the dural graft (white arrow), OsteoVation bone graft (black arrow), and CSF external and internal (stars) to bone graft, ''bathing'' the implant. (B) Postoperative axial CT showing dilation of ventricles and CSF around implant.

Copyright © 2008 Mutaz B. Habal, MD. Unauthorized reproduction of this article is prohibited.

addition, there was pulsatile tissue at the depths of the defect.

A computed tomography (CT) scan without contrast of the head (Fig 1B) revealed growth of an old skull fracture. There was extensive porencephaly and encephalopathic changes extending from the right lateral ventricle to a large cystic cavity. The bone was protuberant over a small rim of dura with underlying tissue causing the bone to protrude outward (Fig 1B).

Cranioplasty Operation

The defect was exposed through an open craniotomy. The outer skull bone defect was 4 × 3 cm, but there was a secondary underlying bone growing through a pseudomembrane of dura. When that bone was removed, there was an extensive dural defect measuring approximately 5 × 8 cm. The edges of the protruding bone were removed from around the skull defect. There was extensive underlying encephalomalacia. A 6 × 8-cm GORE PRECLUDE MVP (W. L. Gore & Associates, Inc, Flagstaff, AZ) graft was sewn over the dural defect. DuraSeal (Confluent Surgical, Inc, Waltham, MA) glue was irrigated over the Nurolon (Ethicon, Inc, Piscataway, NJ) dural stitches. A straight absorbable plate was then placed over the dura. A cranioplasty was performed using 30 mL of OsteoVation (OsteoMed, Addison, TX) hydroxyapatite bone paste to cover the skull defect. Some bone paste was applied anteriorly and inferiorly to shape the contour such that it was flush with the surrounding normal bone. The patient had no new neurologic deficits immediately postoperatively and was discharged 3 days later.

Postoperative Course/Shunt Operation

Two months after initial surgery, the patient developed a pocket of fluid under the skin measuring 8 × 6 × 2 cm. It was palpable over the cranioplasty site. A head CT showed marked hydrocephalus with globally enlarged ventricles (Fig 2B). The CSF was now ''bathing'' the cranioplasty from both sides, as it leaked through the dura away from the dilated ventricles. The hydroxyapatite construct showed no signs of disintegration (Fig 2A), and there was no palpable bony defect.

The hydrocephalus was felt to be secondary to the impaired cerebrospinal absorption from the previous surgery. The child had mild hydrocephalus at bone line that was probably acutely exacerbated by blood and surgical debris, mixing with CSF. This subsequently may have impaired cerebrospinal absorption.

Results

A ventriculoperitoneal shunt was implanted with no acute complications. The swelling in the right parietal scalp area subsided upon shunt implant. The patient remained at his neurologic baseline, awake and alert with a fixed hemiparesis. At 2 and 12 months following the shunt, the implant was still palpably solid without breakdown.

Discussion

The findings of protuberant bone, over a small rim of dura with underlying tissue, causing the bone to protrude outward (Fig 1B), were consistent with a growing skull fracture secondary to a dural defect and underlying brain pulsations.[7] Treatment options were multifold, including autologous bone, acrylic, and shunting. Hydroxyapatite was frequently used at our institution, with occasional breakdown of the implant when exposed to postoperative CSF or seroma.

This is the first documented case of a sustained, functional hydroxyapatite implant exposed on both sides to CSF ''bath.'' Structural integrity was maintained in the implant, clinically and radiographically at 12 months. These results are encouraging from a structural perspective, especially in contrast to a rapid-setting hydroxyapatite, Mimix (Biomet Inc, Jacksonville, FL), a different type of hydroxyapatite, which we have seen disintegrate into tiny pieces upon prolonged contact with CSF.

In this patient, OsteoVation (also known as Callos Inject/Impact) was resistant to disintegration when exposed to a liquid. The structure of OsteoVation—its high flexural strength, high fracture toughness, and compositional similarity to bone—could account for this increased resistance to disintegration. Flexural strength is a mechanical property that is dependent on the inherent resistance of the material to fracture and presence of defects.[8] OsteoVation has a flexural strength of 6.87 MPa, 59% higher than that of Norian CRS (Synthes, Paoli, PA), a frequently used type of hydroxyapatite. The high flexural strength of OsteoVation could be due to a difference in cement reaction chemistry and pore sizes between these materials.[8] Moreover, OsteoVation has high fracture toughness at 48 hours postimplantation, suggesting that it limits crack propagation under long-term physiologic loading.[8] Overall, OsteoVation has greater structural integrity—allowing implantation of the cement before

Copyright © 2008 Mutaz B. Habal, MD. Unauthorized reproduction of this article is prohibited.

hardware placement—than BoneSource (Stryker, Kalamazoo, MI), a first-generation calcium phosphate cement, and Norian SRS[9] (J. Lin et al, unpublished data, 2006). Importantly, OsteoVation and Norian SRS were found to have similar dissolution properties.[10]

The composition and physical properties of OsteoVation were designed to be similar to natural bone. The x-ray diffraction pattern shows that it is similar in composition to natural bone. The Fourier transform infrared spectra show that OsteoVation forms carbonated hydroxyapatite in vivo similar to natural bone, based on results of the material that had been explanted 4 months previously (OsteoVation product brochure; OsteoMed). Furthermore, the physical properties of OsteoVation are different from other commonly used hydroxyapatite cements. OsteoVation has a lower solubility of calcium phosphate compared to calcium sulfate (gypsum) and plaster of paris. Solubility of calcium phosphate is an important measure of hydroxyapatite function because a high solubility of calcium phosphate would create a void before bone could fill in the defect (OsteoVation product brochure; OsteoMed). One in vivo study in humans found that the overall survival rates of hydroxyapatite after 5 and 10 years were 94.4% and 92.8%, respectively, and the accumulative success rates were 89.9% and 54%, respectively.[11]

CONCLUSION

Prolonged exposure to CSF bathing of OsteoVation hydroxyapatite cement implant used in this case did not appear to significantly alter, radiographically or clinically, the durability of the implant. It appears that this product has a good long-term structural and functional stability when exposed to water-based fluids and can be considered a good-choice reconstructive cranial cement.

REFERENCES

1. Mati DB, Manson PN. Biomechanical analyses of hydroxyapatite cement cranioplasty. J Craniofac Surg 2004;15:415–422
2. Miller A, Guerra AB, Biddros RS, et al. A comparison of resistance to fracture among four commercially available forms of hydroxyapatite cement. Ann Plastic Surg 2005;55:87–92
3. Overgaard S, Soballe K, Lind M, et al. Resorption of hydroxyapatite and fluorapatite coatings in man. An experimental study in trabecular bone. J Bone Joint Surg Br 1997;79: 654–659
4. Pang D, Tse HH, Zwienenberg-Lee M, et al. The combined use of hydroxyapatite and bioresorbable plates to repair cranial defects in children. J Neurosurg 2005;102:36–43
5. Magee WP Jr, Ajkay N, Freda N, et al. Use of fast-setting hydroxyapatite cement for secondary craniofacial contouring. Plast Reconstr Surg 2004;114:289–297
6. Burstein FD, Cohen SR, Hudgins R, et al. The use of porous granular hydroxyapatite in secondary orbitocranial reconstruction. Plast Reconstr Surg 1997;100:869–874
7. Muhonen MG, Piper JG, Menezes AH. Pathogenesis and treatment of growing skull fractures. Surg Neurol 1995;43:367–373
8. Lin J, Yetkinler DN, Delaney D, et al. Improved flexural strength of a novel craniomaxillofacial cement. Presented at the 51st Annual Meeting of the Orthopaedic Research Society. Poster no. 1029. Orthopaedic Research Society Transactions. Vol 30. Washington, DC, 2005.
9. Morgan J, Dauskardt RH. Notch strength insensitivity of self-setting hydroxyapatite bone cements. J Mater Sci Mater Med 2004;14:647–653
10. Yetkinler DN, Delaney D, Constantz BR. In vitro and in vivo evaluation of two calcium phosphate cements. Presented at the 50th Annual Meeting of the Orthopaedic Research Society. Poster no. 1520. Orthopaedic Research Society Transactions. Vol. 29. San Francisco, CA, 2004
11. Artzi Z, Carmeli G, Kozlovsky A. A distinguishable observation between survival and success rate outcome of hydroxyapatite-coated implants in 5–10 years in function. Clin Oral Implants Res 2006;17:85–93

Sublingual Ranula: A Closer Look to Its Surgical Management

Carmen Mortellaro, MD, DDS,* Susanna Dall'Oca, DDS, MSD,† Alberta Greco Lucchina, DDS,‡ Antonino Castiglia, DDS,§ Gianpietro Farronato, MD, DDS,‖ Emanuele Fenini, DDS,‖ Gaetano Marenzi, DMD, PhD,¶ Oreste Trosino, DMD,¶ Carlo Cafiero, MD, DDS,¶ Gilberto Sammartino, MD, DDS¶

Torino, Italy

Abstract: Ranulas have been managed by various surgical methods, and the optimal treatment is still controversial. The aim of this study was to analyze a group of 124 surgically treated patients with intraoral ranula to assess 3 different methods: sublingual gland removal combined with the ranula excision, conventional marsupialization, and a variant of the marsupialization technique usually performed in our departments. Recurrence rate was 0% after radical treatment, 25.8% after marsupialization, and 12% after modified marsupialization. We suggest that conservative methods should always be considered as treatment of superficial oral ranulas. The modification of the conventional marsupialization by suturing the edges of the pseudocyst before unroofing of the lesion was demonstrated to be a useful technical strategy that simplifies and accelerates the surgical procedures and probably contributed to preventing recurrences.

Key Words: Ranula, marsupialization, sublingual gland, recurrence

The term ranula is descriptive of true cyst or cystlike formations in the floor of the mouth. The term is derived from the Latin word ''rana'' (which means frog), because of the bluish, fluctuant, translucent, dome-shaped swelling on the floor of the mouth which resembles the underbelly of a frog.

Copyright © 2008 Mutaz B. Habal, MD. Unauthorized reproduction of this article is prohibited.